

Peripheral intravenous Ceftriaxone administration can cause upper extremity deep vein thrombosis in patients with heart failure

Intravenous antibiotics and thrombosis

Adnan Yamanoglu¹, Zeynep Karakaya¹, Nalan Gokce Celebi Yamanoglu², Pinar Yeşim Akyol¹, Fatih Esad Topal¹¹Department of Emergency Medicine, Izmir Katip Celebi University, Ataturk Training and Research Hospital²Department of Emergency Medicine, Izmir Bozyaka Training and Research Hospital, Izmir, Turkey

Abstract

Upper extremity deep vein thrombosis (UE-DVT) can result in pulmonary embolism in one in three patients and entails a high risk of mortality. UE-DVT has to date generally been linked to central venous catheter use and malignancy. Until today, there have been no previous reports of an increased risk of UE-DVT related to peripheral intravenous Ceftriaxone administration in patients with only heart failure (HF) as a risk factor.

We report a case of UE-DVT developing following iv administration of Ceftriaxone via a peripheral cannula with no provoking factor other than HF. This case showed us that Ceftriaxone administered via simple peripheral IV cannula can cause UE-DVT in cases with severe HF. Peripheral intravenous administration of Ceftriaxone may need to be avoided in patients with severe HF.

Keywords

Bedside ultrasound; Ceftriaxone; Heart failure; Intravascular thrombosis; Intravenous cannula

DOI: 10.4328/ACAM.20509 Received: 2021-01-28 Accepted: 2021-03-10 Published Online: 2021-04-16 Printed: 2021-08-15 Ann Clin Anal Med 2021;12(Suppl 3): S351-353

Corresponding Author: Pinar Yeşim Akyol, Izmir Katip Celebi University, Ataturk Training and Research Hospital, Department of Emergency Medicine, Basın Sitesi, Izmir, 35360, Turkey.

E-mail: yesimakyol@gmail.com P: +90 (232) 243 43 43 / +90 (232) 244 44 44 GSM: +90 505 357 29 41 F: +90 (232) 243 15 30

Corresponding Author ORCID ID: <https://orcid.org/0000-0003-2477-1443>

Introduction

Upper extremity deep vein thrombosis (UE-DVT) is a rare clinical entity, representing 1-4% of all deep vein thromboses (DVTs) [1]. In addition to local extremity discomfort, it entails a high risk of mortality as a cause of pulmonary embolism in one in three patients [2]. UE-DVT is classified into two groups. Primary UE-DVT occurs in association with idiopathic causes and anatomical variants, and is rare, with an annual incidence of 1-2/100,000 in the general population [1,3]. Secondary UE-DVT frequently occurs in association with one or more predisposing factors [3] and constitutes approximately 80-90% of all UE-DVT cases [4]. The most common predisposing factors for secondary UE-DVT are central venous cannulation and/or prothrombotic conditions, although kidney failure, history of DVT, history of trauma or surgery, heart failure (HF), and neurological diseases, which are predisposing factors for all DVTs, also constitute risk factors for UE-DVT [3].

Some medications are also known to be linked to UE-DVT [5]. However, we encountered no previous studies or case reports of an increased risk of DVT with Ceftriaxone use via the peripheral intravenous (IV) route in cases of HF.

We report a case of UE-DVT, which developed following Ceftriaxone administration via the peripheral IV route in a patient with no identified provoking factor for DVT other than HF. This case is reported since it involves a novel side-effect that may limit the use of Ceftriaxone via the peripheral route or else require particular care in patients with HF.

Case Report

A 56-year-old man presented to the emergency department (ED) due to pain and swelling in the right arm. He had only a history of coronary artery disease and subsequent HF. There was a history of chronic use of aspirin and ramipril + hydrochlorothiazide. There was no history of smoking, and no any other illegal substance or drug use. A detailed history revealed that the patient had presented to our hospital ED three days previously due to cough, fever and respiratory difficulty, and that pneumonia was diagnosed after tests. The patient was injected with 2 gr of Ceftriaxone in 150 cc of isotonic saline through a peripheral IV cannula in the right arm, and the patient was discharged with Ciprofloxacin group oral antibiotics. No other drug was administered through the same vascular access, and the cannula was removed during discharge. The patient again presented to ED with pain and redness in the right arm and with aggravated dyspnea. Extremity examination revealed a rash and edema beginning from the earlier cannula insertion site in the antecubital region of the right arm and extending toward the arm (Figure 1 a, b).

Bedside ultrasound for assessment of heart revealed a severely reduced left ventricular systolic function, biatrial dilatation and pleural effusion (Figure 2 a, b, c). Bedside ultrasound for vascular assessment of upper extremity revealed thrombophlebitis at the cephalic and basilic veins and UE-DVT at the subclavian, brachial and axillary veins (Figure 3). On thoracic CT angiography, there was no pulmonary embolism, while pneumonic infiltration and consolidation were determined in the upper lobe of the right lung, together with bilateral pleural effusion. The patient was hospitalized. No Mycobacterium tuberculosis

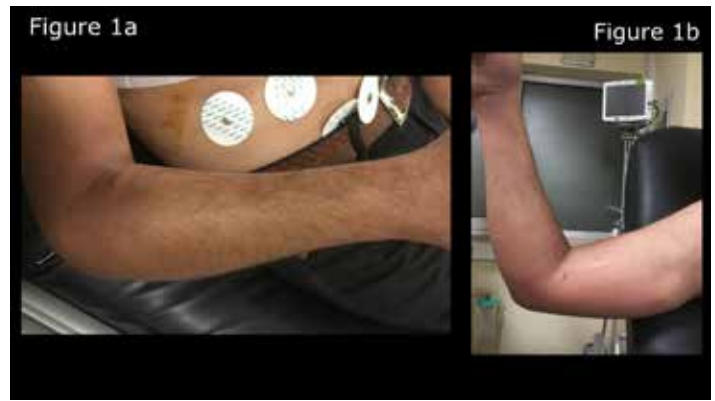

Figure 1a. Redness and swelling are seen at the entrance of the peripheral intravenous cannula in the right arm; **1b.** It appears that the redness and swelling reach up to the axilla of the right arm

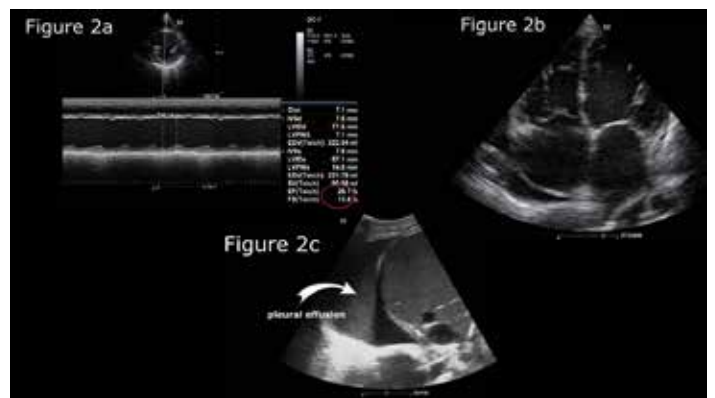


Figure 2a. Left ventricular function assessment at parasternal short axis with Teichholz method revealed the severe reduced left ventricle ejection fraction; **2b.** Echocardiographic assessment at apical four-chamber view revealed biatrial dilatation, signs of dilated cardiomyopathy, and pericardial effusion around the right atrium; **2c.** At right-sided pleural assessment revealed massive pleural effusion

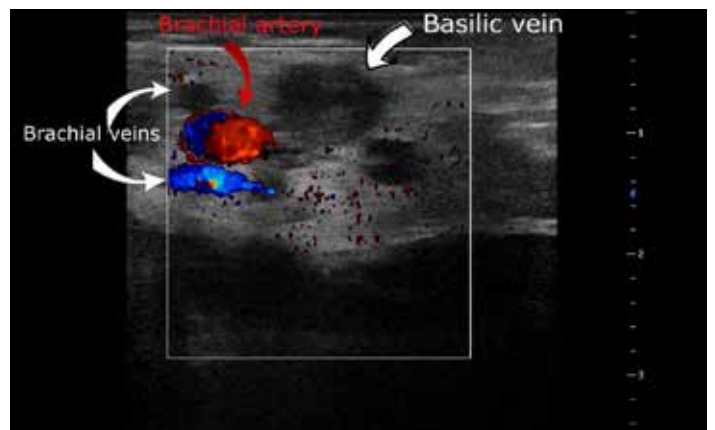


Figure 3. Bedside vascular ultrasound revealed thrombophlebitis at the basilic vein and deep venous thrombosis at the brachial vein. Bedside ultrasound for vascular assessment of upper extremity revealed thrombophlebitis beginning from the cephalic vein and progressing inside the subclavian vein, and beginning at the basilic vein and extending inside the axillary vein, also including the brachial vein.

complex, *Streptococcus pneumoniae*, *Staphylococcus aureus*, *Haemophilus influenzae*, *Moraxella catarrhalis*, and *Klebsiella pneumoniae* growth was observed in sputum and blood cultures. Anti-HCV, Anti HIV, HBSAG, HIV Ag / Ab, and Anti HbC IgM values were negative. The patient's homocysteine was within normal limits at 10.70 $\mu\text{mol/L}$, Anti-ds DNA tested using IFT and EIA was negative, and anti-Beta2 glycoprotein 1 antibody IgM (1.23 U/ml) and IgG (4.32 U/ml) levels were negative. The lupus anticoagulant confirmatory test was negative, p-ANCA (1.36 U/ml), c-ANCA (0.32 U/ml), antinuclear antibody (FANA) (IFA), ACA IgM (1.84 GPL/ml) and IgG (2.7 GPL/ml) were negative, antithrombin, protein C and protein S levels were within normal ranges, and activate protein C was greater than 2.1. Since activated protein C resistance was not determined. A signed consent form was obtained from the patient.

Discussion

Genetic or acquired thrombophilic disorders leading to hypercoagulation are estimated to increase the risk of UE-DVT approximately 5-6-fold, although the mechanism by which hypercoagulable states contributes to DVT formation is still unclear [6]. Thrombophilic disorders include antithrombin III, protein C and protein S deficiency, Factor V Leiden and prothrombin gene G20210A polymorphism, antiphospholipid antibodies (lupus anticoagulant and anti-cardiolipins) [6]. The listed inherited thrombophilia disorders were subjected to laboratory tests, with the exception of Factor V Leiden, and the test results were negative for these. No need for genetic tests for Factor V Leiden was felt in the absence of activated protein C resistance and medical history.

Virchow's triad is a widely recognized approach for explaining the risk of DVT formation. According to Virchow's triad, in order for a clot to form on the vascular bed, either a flaw must be present in the vascular endothelium, or the blood flowing in the vascular bed must be impaired such as to cause thrombophlebitis, or stasis and pooling must be present in the region. Among these factors, impairment of the vascular endothelium and blood damage frequently appear in association with an acquired or genetic disease. However, stasis can also cause DVT even in healthy individuals without other risk factors following long journeys or major operations, particularly in the lower extremities, which are more affected by gravity. No inherited or acquired disease that might give rise to either endothelial damage or thrombophilia was determined in our patient, although HF capable of causing stasis was present. However, thrombosis would be expected to form primarily in the lower extremities that work against gravity in individuals with a disease such as heart failure that reduces blood flow in the entire body. In our case, thrombosis developed in the upper extremity following IV drug administration and occurred in a form following a vascular pattern, in other words, suggesting superficial thrombophlebitis. It subsequently spread, causing diffuse edema and pain in the proximal and medial aspects of the upper extremity. This also suggests that a DVT developed that proceeded from the superficial to the deep veins following a superficial thrombophlebitis. It is stated in the prospectus information that Ceftriaxone may cause <1% thrombophlebitis (available at: https://www.rxlist.com/rocephin-drug.htm#side_

effects). In subsequent checks, macrolide group antibiotic was administered from the same vascular access from the other arm, and the vascular access was changed at 2-3 days intervals. The treatment continued in this manner, and no similar problem was observed.

Chemical agents reported in the etiology of UE-DVT include potassium chloride, diazepam, the antibiotics vancomycin and oxacillin, and a significant proportion of chemotherapeutic agents, and hypotonic (<250 mosm) and hypertonic (>350 mosm) solutions [5]. Even with these agents, DVT has frequently been reported in association with central catheters and malignancy, and in association with these drugs by the peripheral route, superficial thrombophlebitis has been more reported more than DVT [5].

Active infection can create a predisposition for thrombosis. This risk has previously been reported in association with infections growing in peripherally located central catheters [7]. The greatest association with thrombosis among systemic infections has been reported with cytomegalovirus infection, although underlying immunosuppression malignancy has been reported in the majority of those cases [8]. Ceftriaxone administered via simple peripheral IV cannula may result in UE-DVT in cases with severe HF with no other risk factor. Therefore, it may be necessary to avoid applying Ceftriaxone by the peripheral intravenous route in patients with severe heart failure.

Scientific Responsibility Statement

The authors declare that they are responsible for the article's scientific content including study design, data collection, analysis and interpretation, writing, some of the main line, or all of the preparation and scientific review of the contents and approval of the final version of the article.

Animal and human rights statement

All procedures performed in this study were in accordance with the ethical standards of the institutional and/or national research committee and with the 1964 Helsinki declaration and its later amendments or comparable ethical standards. No animal or human studies were carried out by the authors for this article.

Conflict of interest

None of the authors received any type of financial support that could be considered potential conflict of interest regarding the manuscript or its submission.

References

1. Isma N, Svensson PJ, Gottsäter A, Lindblad B. Upper extremity deep venous thrombosis in the population-based Malmö thrombophilia study (MATS). *Epidemiology, risk factors, recurrence risk, and mortality. Thromb Res.* 2010;125(6):e335-8.
2. Prandoni P, Polistena P, Bernardi E, Cogo A, Casara D, Verlato F, et al. Upper-extremity deep vein thrombosis: risk factors, diagnosis and complications. *Arch Intern Med.* 1997; 157(1):57- 62.
3. Lindblad B, Tengborn L, Bergqvist D. Deep vein thrombosis of the axillary-subclavian veins: epidemiologic data, effects of different types of treatment and late sequelae. *Eur J Vasc Surg.* 1988; 2(3):161-5.
4. Otten TR, Stein PD, Patel KC, Mustafa S, Silbergleit A. Thromboembolic disease involving the superior vena cava and brachiocephalic veins. *Chest.* 2003; 123(3):809-12.
5. Skillman, JJ. Superficial phlebitis: Inflammatory, infectious associated with deep vein thrombosis. In: *Decision Making in Vascular Surgery*, Cronenwett, JL, Rutherford, RB, editors. NY: WB Saunders; 2001.
6. Martinelli I, Battaglioli T, Bucciarelli P, Passamonti SM, Mannucci PM. Risk factors and recurrence rate of primary deep vein thrombosis of the upper extremities. *Circulation.* 2004; 110(5):566-70.
7. Thornburg CD, Smith PB, Smithwick ML, Cotton CM, Benjamin Jr DK. Association between thrombosis and bloodstream infection in neonates with peripherally inserted catheters. *Thromb Res.* 2008; 122(6):782-5.
8. Justo D, Finn T, Atzmony L, Guy N, Stinvil A. Thrombosis associated with acute cytomegalovirus infection: A meta-analysis *Eur J Intern Med.* 2011;22(2):195-9.

How to cite this article:

Adnan Yamanoglu, Zeynep Karakaya, Nalan Gokce Celebi Yamanoglu, Pınar Yeşim Akyol, Fatih Esad Topal. Peripheral intravenous Ceftriaxone administration can cause upper extremity deep vein thrombosis in patients with heart failure. *Ann Clin Anal Med* 2021;12(Suppl 3): S351-353